



Internal and external root resorptions by Cone Beam Computed Tomography (CBCT)

D.D.S., PhD Gabriel Alvarado-Cárdenas, D.D.S. Christi Canché-Dzul, D.D.S., PhD Rafael Hoyos-Pinzón, D.D.S., PhD María López-Villanueva, D.D.S., PhD Marco Ramírez-Salomón, D.D.S., PhD Elma Vega-Lizama. Autonomous University of Yucatan



INTRODUCTION

Root resorptions are asymptomatic pathologies and therefore complex to diagnose, these can be detected in clinical and radiographic examinations that the patient is performed routinely control, due to its infrequency and its asymptomatic way of presenting itself is considered relevant to conduct an investigation that allows us to know the prevalence of root resorptions in patients who come to the FOUADY. This study, through its three-dimensional evaluation with the use of CBCT, will allow us to diagnose the type of resorption and the degree of affectation of the root structures. This research will provide us with quantitative information on the number of root resorptions that occur in the FOUADY, which will allow us to know the prevalence with which we face this type of pathology in the clinic for its treatment.

METHODS & MATERIAL

Observational, descriptive and retrospective study. A database of CT scans stored at the FOUADY in the area of the Endodontics Postgraduate Clinic was used. The dental tomograph with i-CAT Vision software was used for its analysis and interpretation, sagittal and coronal slices of the teeth that met the inclusion criteria were analyzed.

According to the presence of resorption, it was specified with the classification. For apical external root resorption, it was complemented with the Levander classification with a score of 0-4. For internal resorptions, the location was analyzed according to the coronal, middle and apical third for classification. During the sampling, data on sex and age were taken, the number of teeth was counted and for each tomography the planes were placed according to the axes of each tooth for its visualization without distortion in each tooth.

Each tooth was observed from the outermost to the innermost face of each side of the tooth and likewise from the most apical to the most coronal until any area with loss of root contour representing root resorption could be visualized. This was done in all the maxillary and mandibular teeth that presented each tomography.

The data collected were captured and organized in the Excel program, to be later analyzed and represented in tables. The CT scans in this study were selected from the FOUADY database where the information was collected through the 3D radiographic images of the i-CAT Vision software. The CT scans were selected according to the inclusion and exclusion criteria.


RESULTS

In the present study, 310 CT scans stored in the database of the Endodontics Postgraduate Program of the UADY during the period from 2018 to 2022 were analyzed.

Of the total 310 CT scans, 58 resorptions were found in 32 females and 25 males; that is, a prevalence of 18.70% was found. A total of 5 (1.6%) internal resorptions and 53 (17.09%) external resorptions were found in the total sample. The frequency of internal root resorptions was not high, since only 5 resorptions were found. The dental organs that presented internal resorption were in O.D. 1.4, 2.1, 2.3, 3.1 and 3.5 representing a total of 1.6% of the total sample.

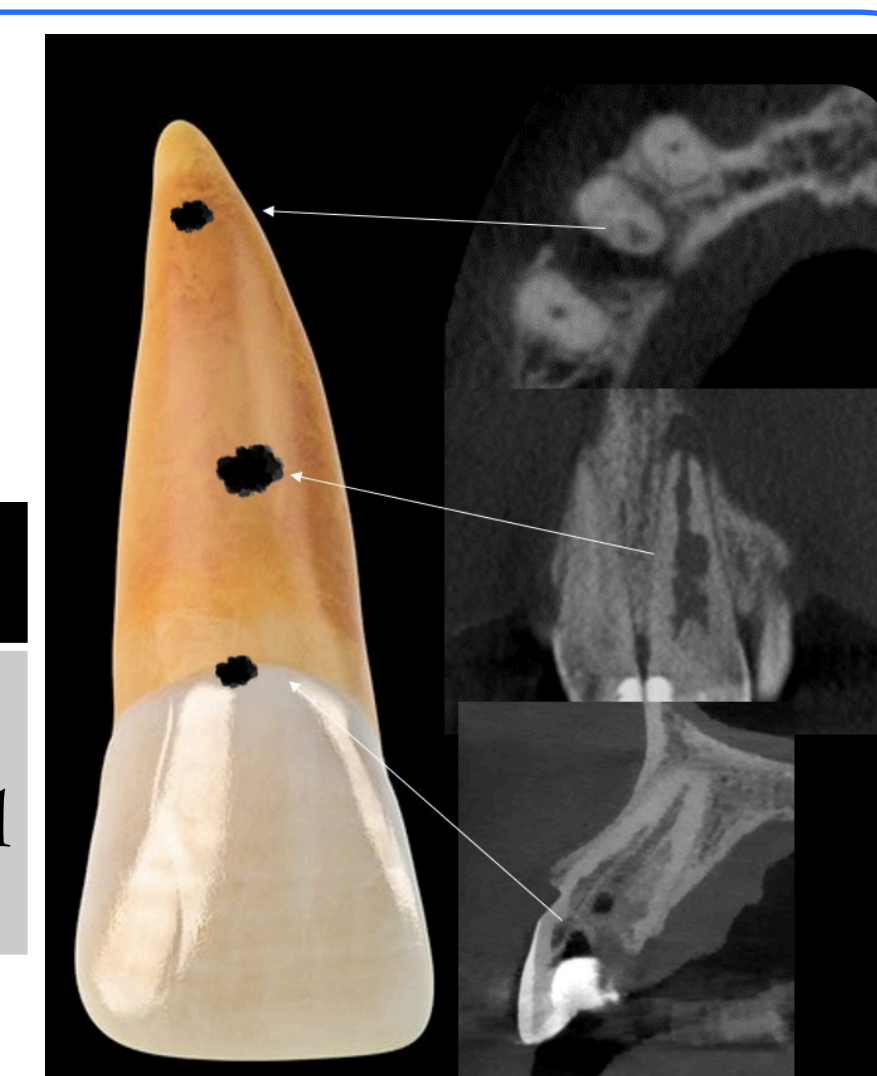
In relation to external root resorptions, a total of 53 resorptions were found, equivalent to 17.09% of the total sample, with the upper and lower central incisors having the highest frequency of resorption, followed by the lower first molars. with the highest frequency of resorption, followed by the lower first molars. According to the degree of destruction of the external root resorptions, we used the Levander classification, in which we observed a grade 3 of frequent destruction in most of the external resorptions in both the maxillary and mandibular dental organs.

Grade 0	Grade 1	Grade 2	Grade 3	Grade 4
Absence of root resorption	Normal root length, irregular shape	Resorption moderate. Loss -2mm	Loss of 2 mm up to 1/3 of the root length	Loss +1/3 of root length



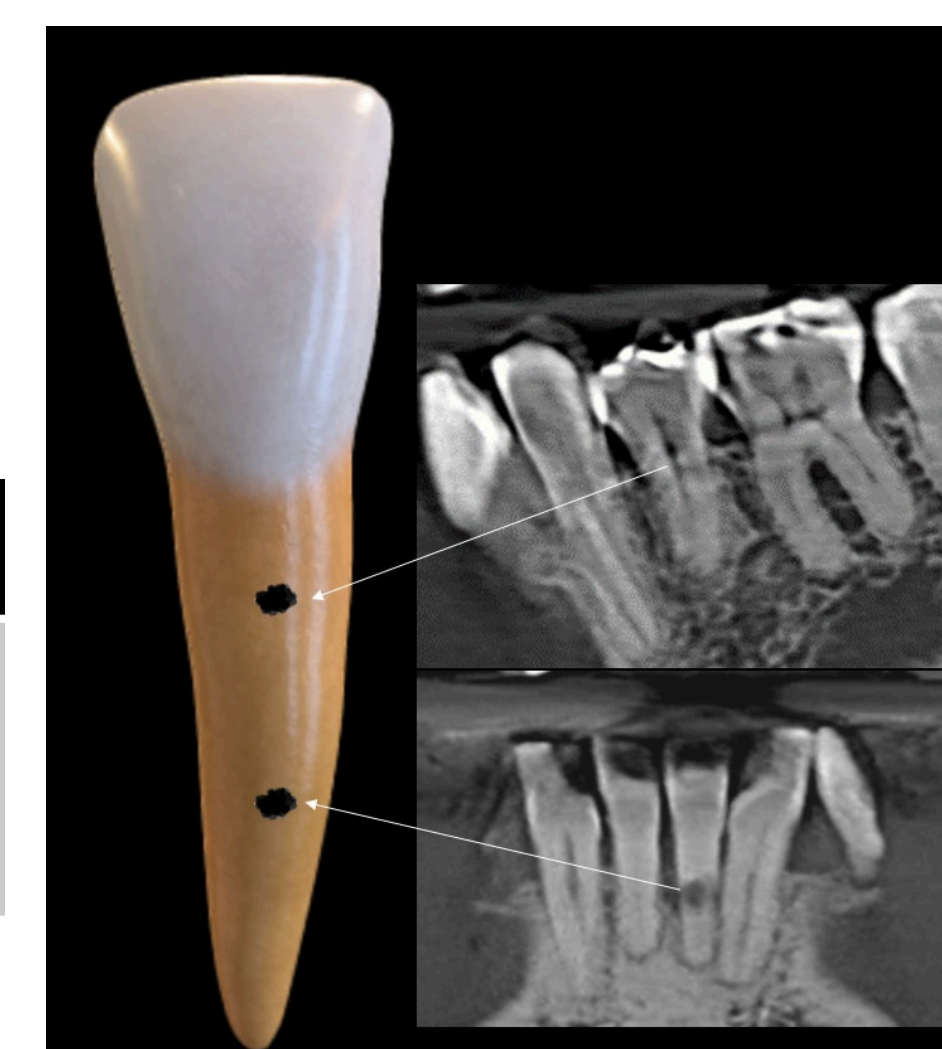
Internal Root Resorption (1.6%)

OD	1.4	2.1	2.3
Affected radicular third	Apical	Middle	Cervical



Internal Root Resorption (1.6%)

OD	3.1	3.5
Affected radicular third	Middle	Medio



CONCLUSION

According to the results obtained, the frequency of root resorptions was 18.70% of a sample of 310 CT scans. The frequency of internal root resorptions was 1.6% of a sample of 310 tomographies analyzed. The frequency of external root resorptions was 17.09% of the total sample. No single dental organ was found with the highest frequency of internal root resorption, since they were found in 5 different dental organs (O.D 1.4, 2.1, 2.1, 2.3, 3.1 and 3.5), but it can be concluded that the anterior sector is the area with the highest frequency of internal root resorption. The teeth with the highest frequency of external root resorption were the upper central incisors.

REFERENCES

Patel S, Ricucci D, Durak C, Tay F. Internal root resorption: a review. *J Endod.* 2010 ;36(7):1107-21.

Patel S, Pitt Ford T: Is the resorption external or internal. *Dent Update.* 2007;34:218.

Tronstad L. Root resorption: etiology, terminology and clinical manifestations. *Endod Dent Traumatol* 1988;4:241-52.

Trope M. Ro ot resorption of dental and traumatic origin: classification based on etiology. *Pract Periodontics Aesthet Dent* 1998;10:515-22.

Zuñiga I, Ramirez M, Escoffié M, Herrera J. Resorción radicular en pacientes de ortodoncia. Revisión bibliográfica y bibliométrica. *Rev Odontol Latinoam.* 2017;9(1):1-8.

Ramos Fonnegra, DC, Ramos Pineda, SL, y Rangel Rueda JD. Prevalencia de reabsorción radicular evaluada en tomografías Cone Beam [Tesis de Especialización]. Universidad Santo Tomás, Bucaramanga, Colombia: 2019.

Marinescu IR, Bănică AC, Mercuț V, Gheorghe AG, Drăghici EC, Cojocaru MO, Scricieiu M. Resorption Diagnostic: Role of Digital Panoramic Radiography. *Curr Health.*

